

## SHORT COMMUNICATION

# Subcutaneous dirofilariasis in southern India: a case report

Cases of zoonotic filariasis, caused by filarial nematodes transmitted mostly by zoo-anthropophilic vectors, occur world-wide, apparently with increasing incidence (Orihel and Eberhard, 1998; Maltezos *et al.*, 2002). In humans, the parasites causing zoonotic filariasis, which are mostly *Dirofilaria* spp., are usually recovered from subcutaneous tissue (Maltezos *et al.*, 2002; Athari, 2003). The symptoms that signal their presence in humans include transitory inflammatory swellings or nodules, which may or may not be tender.

Although about 40 different species of *Dirofilaria* are recognized, fewer than six are known to cause human infections (Sekar *et al.*, 2000; Ashford and Crewe, 2003). The species infecting people varies with geographical area (Orihel and Eberhard, 1998). In the U.S.A., for example, *D. tenuis*, a parasite of raccoons, is the species mostly commonly found in humans, whereas *D. repens*, a parasite of dogs and cats, causes most of the cases of human dirofilariasis detected in Europe, Asia and Africa (Orihel and Eberhard, 1998; Mallick and Ittyerah, 2003). Human dirofilariasis has not been widely recognized in India but there is probably a focus of human infection with *D. repens* in Kerala (George and Kurian, 1978; Sekar *et al.*, 2000; Mallick and Ittyerah, 2003), and the disease is relatively common in Sri Lanka (Sekar *et al.*, 2000; Mallick and Ittyerah, 2003), which is geographically close to southern India. Most of the few documented cases of human dirofilariasis recorded in India have had ocular infections, although two Indian patients with subcutaneous dirofilariasis have also been reported (Bhatt, 2003;

Mallick and Ittyerah, 2003). A third case of subcutaneous dirofilariasis from India is described below.

### CASE REPORT

In June 2004, a 35-year-old male resident of the town of Vellore, in Tamil Nadu, southern India, presented at the Christian Medical College (CMC) in the town, asking that a thread-like structure, that he had removed from a blister on his lip a few hours previously, be identified. He appeared healthy but complained of having had a painful facial swelling over the previous 3 days. When the man had first noticed the swelling, it measured approximately 1 × 1 cm and was on the left side of his forehead. A day later, however, the swelling appeared to have moved to the right side of the man's forehead, and on the following day the swelling had disappeared but a painful blister had developed on the man's lower lip. When the man attempted to rinse his mouth with warm water, this blister burst, revealing the white thread-like structure. The man extracted this structure, which was a 12.5-cm-long, 0.6-mm-wide nematode (Fig. 1), and took it to the CMC for identification. At the CMC, the man said he had been to Kerala about a year earlier. He was checked for microfilaraemia, by bloodsmear examination, but was found to be amicrofilaraemic.

Under the microscope, the outer surface of the nematode's cuticle was found to have fine transverse striations and prominent longitudinal ridges (Fig. 2), the latter being especially conspicuous when the nematode

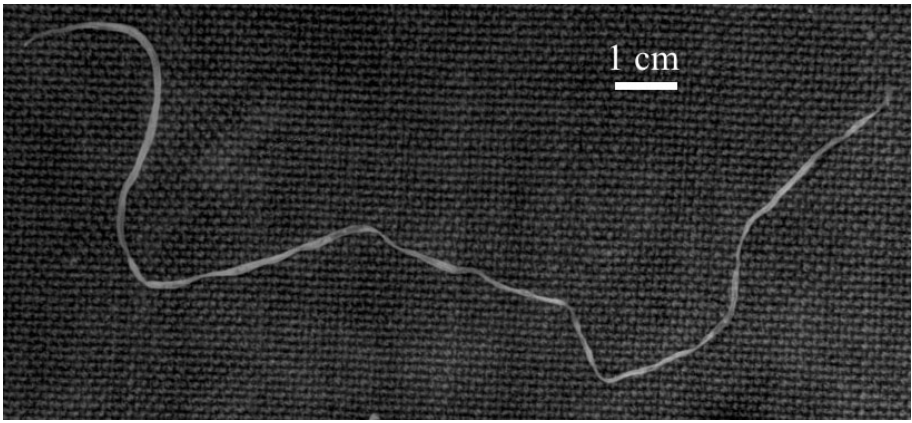


FIG. 1. The nematode after its removal from the lip blister.

was examined without a coverslip. The body cavity contained a female reproductive system, with the vulva about 1 mm from the anterior end. The proximal portion of the vagina was bulbous. The vagina looped and ended in a uterine bifurcation. The uteri almost filled the body cavity. The ovaries and oviducts were highly coiled.

The nematode was then fixed, dehydrated, cleared and embedded in paraffin

wax, so that cross sections could be cut and stained with haematoxylin and eosin. The stained sections (Fig. 3) revealed a cuticle that was approximately 8  $\mu\text{m}$  thick. The outermost layer had prominent longitudinal ridges, each separated from the next by a distance greater than the width of a ridge. In one section, four chord nuclei were visible. The muscle layer below the cuticle was well developed and the body cavity showed two




FIG. 2. A micrograph of part of the nematode, showing the fine, transverse striations and longitudinal ridges in the cuticle.

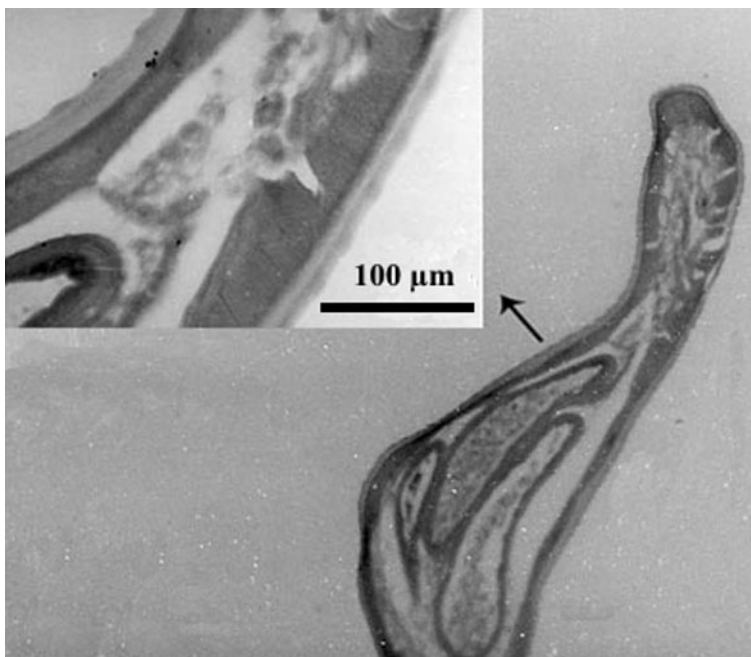


FIG. 3. Histological cross-section of part of the nematode, at low and (inset) high magnification, showing the outer longitudinal ridges, paired uteri and intestinal tube. Haematoxylin and eosin.

large uteri and an intestinal tube. Based on these features, the worm was identified as an adult, female *D. repens*.

## DISCUSSION

*Dirofilaria repens* is the main and perhaps sole cause of subcutaneous dirofilariasis in humans in Asia, including India (Mallick and Ittyerah, 2003). Almost all human infections caused by *D. repens* are localized in the upper part of the body, mostly in and around the eyes (Maltezos *et al.*, 2002). The infection may be asymptomatic or present as a migratory swelling, which may or may not be tender. Occasionally, human dirofilariasis is detected many years after the initial infection, when the worm has died and been enveloped in a foreign-body granuloma.

The genus *Dirofilaria* has two subgenera: *Dirofilaria* and *Nochitella*. While the nematodes in the subgenus *Dirofilaria* have smooth cuticles and are typically found in

the pulmonary arteries, those in the subgenus *Nochitella* (of which *D. repens* is the type species) have longitudinal cuticular ridges and are usually found in subcutaneous tissue (Beaver and Orihel, 1965; Athari, 2003). In humans, who are accidental and 'dead-end' hosts of *Dirofilaria*, any inoculated larvae that survive take about 5 months to develop into adults (Beaver and Orihel, 1965; Orihel and Eberhard, 1998; Sekar *et al.*, 2000). Female worms are found more frequently than males, in a ratio of approximately 3:1 (Orihel *et al.*, 1997), and most human infections only involve a single adult nematode (Sekar *et al.*, 2000). Although the female worms may become sexually mature in humans, they are usually infertile, because of the absence of male worms, and *Dirofilaria* microfilaraemias are therefore very rare in humans (Athari, 2003).

Identification of *Dirofilaria* to genus is relatively easy but subsequent identification to species level is difficult (Athari, 2003), and often simply based on the geographical area from which the nematode came (Orihel

and Eberhard, 1998). Although adult *D. repens* and *D. tenuis* are morphologically similar, there is only a single, unsubstantiated report of *D. tenuis* in India (Bhatt, 2003), and most parasitologists believe that *D. tenuis* is restricted to the U.S.A. (Pacheco and Schofield, 1965; Ashford and Crewe, 2003; Bhatt, 2003). The size and nature of the ridges on the worm discussed here are indicative of *D. repens*.

The first reported case of human ocular dirofilariasis in India occurred in Kerala in June 1976 (Joseph *et al.*, 1977). At least three similar cases have since been observed in Kerala (George and Kurian, 1978; Sekar *et al.*, 2000; Mallick and Ittyerah, 2003) and it seems quite likely that the present case had been infected while visiting this state.

This article appears to represent the first report of *D. repens* in India causing subcutaneous infections anywhere but close to the eye. Dirofilariasis should be considered as a differential diagnosis for migratory subcutaneous swellings and conjunctival nodules in Kerala and elsewhere in southern India.

Treatment by removal of the worm is usually simple and effective (Sekar *et al.*, 2000). There is usually no need for chemotherapeutic intervention as microfilaraemia is extremely rare (Orihel and Eberhard, 1998).

P. PADMAJA  
Department of Clinical Microbiology,  
Christian Medical College,  
Vellore – 632004, India

KANAGALAKSHMI  
Department of Staff Students Health  
Service,  
Christian Medical College,  
Vellore – 632004, India

R. SAMUEL  
Department of General Pathology,  
Christian Medical College,  
Vellore – 632004, India

P. J. KURUVILLA  
Department of Staff Students Health  
Service,  
Christian Medical College,  
Vellore – 632004, India

E. MATHAI  
Department of Clinical Microbiology,  
Christian Medical College,  
Vellore – 632004, India

Received 20 October 2004,  
Revised 24 January 2005,  
Accepted 26 January 2005

Reprint requests to: P. Padmaja. E-mail: dhittu\_padma@yahoo.co.in; fax: +91 416 2232035.

## REFERENCES

- Ashford, R. W. & Crewe, W. (2003). *The Parasites of Homo sapiens*. London: Taylor & Francis.
- Athari, A. (2003). *Archives of Iranian Medicine*, **6**, 63–65.
- Bhatt, K. G. (2003). *Indian Journal of Medical Microbiology*, **21**, 65.
- Beaver, P. C. & Orihel, T. C. (1965). *American Journal of Tropical Medicine and Hygiene*, **14**, 1010–1029.
- George, M. & Kurian, C. (1978). *Journal of the Indian Medical Association*, **71**, 123–124.
- Joseph, A., Thomas, P. G. & Subramaniam, K. S. (1977). *Indian Journal of Ophthalmology*, **24**, 20–22.
- Mallick, D. & Ittyerah, T.P. (2003). *British Journal of Ophthalmology*, **15th January** (online video report).
- Maltezos, E. S., Siviridis, E. L., Giatromanolaki, A. N. & Simopoulos, C. E. (2002). *Scottish Medical Journal*, **47**, 86–88.
- Orihel, T. C. & Eberhard, M. I. (1998). *Clinical Microbiology Reviews*, **11**, 366–381.
- Orihel, T. C., Helentjaris, D. & Alger, J. (1997). *American Journal of Tropical Medicine and Hygiene*, **56**, 452–455.
- Pacheco, G. & Schofield Jr, H. L. (1968). *American Journal of Tropical Medicine and Hygiene*, **14**, 180–182.
- Sekar, H. S., Srinivasa, H., Battu, R. R., Mathai, E., Shariff, S. & Macaden, R. S. (2000). *Indian Journal of Pathology and Microbiology*, **43**, 77–79.