

ULTRASONOGRAPHIC DETECTION OF LIVING ADULT *WUCHERERIA BANCROFTI* USING A 3.5-MHZ TRANSDUCER

GERUSA DREYER, ABIEL SANTOS, JOAQUIM NOROES, FERNANDO AMARAL, AND DAVID ADDISS

Departamento de Parasitologia, Centro de Pesquisas Aggeu Magalhaes-FIOCRUZ, Recife, Brazil; Hospital das Clinicas, Universidade Federal de Pernambuco, Recife, Brazil; Medix, Memorial Imagem e Diagnostico, Recife, Brazil; Division of Parasitic Diseases, Centers for Disease Control and Prevention, Atlanta, Georgia

Abstract. Adult *Wuchereria bancrofti* can be readily detected by ultrasound in the lymphatic vessels of the spermatic cord with a 7.5-MHz transducer, but most ultrasound machines in developing countries are equipped with 3.5-MHz transducers. To assess the potential for ultrasound as a tool for diagnosis and epidemiologic assessment in lymphatic filariasis, we compared the performance of 3.5-MHz and 7.5-MHz transducers in 61 men in Recife, Brazil. All men had three ultrasound examinations using a 3.5 MHz transducer and an examination with a 7.5-MHz probe. Using the 7.5-MHz transducer, adult *W. bancrofti* were detected in 41 men; 81 adult worm nests were detected. Sixty-four (79%) nests were detected with the 3.5-MHz probe, each on all three examinations. The 3.5-MHz probe correctly identified 35 (85.4%) of 41 men as infected; sensitivity increased with lymphatic vessel diameter. Ultrasonographic examination with a 3.5-MHz transducer is a sensitive method for detection of adult *W. bancrofti* in men and merits consideration as a tool for rapid epidemiologic assessment.

With an estimated 120 million infected persons, lymphatic filariasis is an important public health problem in tropical areas of the world.¹ An estimated 90% of these infections are caused by the parasitic worm *Wuchereria bancrofti*. Although many infected persons are asymptomatic, an estimated 40 million have filaria-associated lymphedema or testicular hydrocele.¹ The medical, social, and economic costs of these sequelae are enormous;^{1–4} lymphatic filariasis is considered the second leading cause of disability worldwide.⁵

Ultrasound is increasingly used for diagnosis and clinical studies of parasitic diseases such as schistosomiasis and echinococcosis,^{6,7} and recently it has been shown to be a powerful tool for the study of lymphatic filariasis. In 1994, Amaral and others first reported using ultrasound to visualize adult *W. bancrofti* in the scrotal area of infected men.⁸ They described a continuous, distinctive, and specific pattern of worm movement called the filaria dance sign. When surgery was performed on patients who exhibited this sign, nests of adult *W. bancrofti* were found in the lymphatic vessels of the spermatic cord.⁸ Extensive clinical and surgical experience has confirmed these initial findings (Dreyer G, unpublished data),^{9,10} and ultrasound examinations of men from nonendemic areas have failed to detect the filaria dance sign.^{11–13} The location of the adult worm nests within the lymphatic vessels remains remarkably stable with time.¹⁴ Detection of the filaria dance sign subsequently has been used to diagnose *W. bancrofti* infection in both men and women and to directly assess the efficacy of antifilarial drugs against the adult worm.^{9,15–18}

Virtually all ultrasound studies of lymphatic filariasis have used 5.0- or 7.5-MHz transducers, which provide good resolution of the superficial and dilated lymphatic vessels of the spermatic cord. With a 7.5-MHz transducer, the filaria dance sign can be detected in the scrotal area of at least 80% of men with microfilaremia (Dreyer G, unpublished data)¹³ and in a significant proportion of infected men who are microfilaria-negative in 1 ml of filtered blood.¹⁹ However, the need for a 7.5-MHz transducer greatly limits the use of ultrasound for diagnosis and study of lymphatic filariasis. Ultrasound machines for obstetrical use are available in many hospitals and clinics in developing countries, but these ma-

chines are usually equipped with 3.5-MHz transducers. The 3.5-MHz transducers generally produce greater tissue penetration and are useful for visualizing internal organs, but they are less suitable for examination of superficial structures. Because the filaria dance sign is so characteristic, we wished to assess the potential for using a 3.5-MHz transducer for field diagnosis and screening for lymphatic filariasis. We compared the performance of ultrasound with 3.5- and 7.5-MHz transducers to detect the filaria dance sign in the scrotal area of infected men.

MATERIALS AND METHODS

The study protocol was approved by the Ethical Review Board of Hospital das Clinicas, Universidade Federal de Pernambuco (Recife, Brazil). Sixty-one men, all asymptomatic long-term residents of greater Recife, were enrolled in the study after written informed consent was obtained. Before the study began, all patients had 1 ml of blood collected between 11:00 PM and 1:00 AM; the blood was passed through a 3- μ m Nuclepore filter (Nuclepore, Pleasanton, CA) and examined for microfilariae. Men who were microfilaria-negative in 1 ml of blood had additional specimens of 5 ml and 10 ml collected on subsequent weeks before being considered microfilaria-negative. Patients were unaware of the results of their blood test or ultrasound examinations until the end of the study. Men who were microfilaria-positive and those who had adult *W. bancrofti* detected on ultrasound examination were treated at the end of the study with diethylcarbamazine or ivermectin.

All 61 men underwent ultrasonographic examinations of the scrotal area by one of two investigators using a Pio Medical Scanner 200 ultrasound machine with a 7.5-MHz transducer. The location of the adult worm nests and the diameter of the lymphatic vessels at the site of the adult worm were recorded. A third investigator, who was blinded to the patient's microfilaremia status and ultrasound results, independently examined the scrotal area of each patient using a Pio Medical portable ultrasound machine with a 3.5-MHz probe. Three such examinations were performed, once a week for three weeks. At the end of the three-week study, the senior

TABLE 1

Characteristics and ultrasonographic findings for 41 men with a filaria dance sign (FDS) detectable by ultrasound using a 7.5-MHz transducer and 20 men with no detectable FDS in Recife, Brazil

Characteristic	FDS-positive	FDS-negative
Number of men	41	20
Mean age (range), years	21.1 (17–34)	20.5 (18–30)
No. (%) of men microfilaria-positive*	39 (95.1)	0*
Geometric mean microfilarial density (range)	144 (1–4,030)	0
No. (%) FDS-positive with a 3.5-MHz probe	35 (85.4)	0
No. of adult worm nests (total, median, range)	81, 2, 1–5	0
No. (%) detected by a 3.5-MHz probe	64 (79)	0

* Men were not considered to be microfilaria-negative until a total of 16 ml of blood, collected between 11:00 PM and 1:00 AM, had been filtered and examined microscopically for microfilaria.

investigator independently confirmed the initial ultrasound examination results using the 7.5-MHz probe.

Statistical methods. The chi-square test was used to determine the significance of differences between proportions and the Wilcoxon rank sum test was used to compare continuous variables (vessel diameter, age, and geometric mean microfilarial density). Statistical tests involving geometric mean microfilarial density were based on log-transformed values. Linear regression and analysis of variance were used to assess the linear relationship between log microfilarial density and number of adult worm nests.

RESULTS

Using a 7.5 MHz transducer, the filaria dance sign was detected in the lymphatic vessels of the spermatic cord in 41 (67.2%) of 61 men. Mean age was similar for men with and without a detectable filaria dance sign (Table 1). Of the 41 men who had a detectable filaria dance sign, 39 (95.1%) were microfilaria-positive, with a geometric mean microfilarial density of 144/ml of blood. A total of 81 adult worm nests were detected in these 41 men (median = 2, range = 1–5) (Figure 1). Of the 81 nests, 33 (40.7%) were detected in the left hemiscrotum and 48 (59.3%) were found in the right hemiscrotum; 17 (41.5%) men had nests detected bilaterally. Geometric mean microfilarial density was higher in men with bilateral filaria dance signs (338/ml) than in men with unilateral involvement (70/ml; $P = 0.05$). The number

of adult worm nests in each man was positively associated with log microfilarial density ($R^2 = 0.19$, $P = 0.004$).

In relation to the testicle, 24 (29.6%) adult worm nests were suprastesticular, 14 (17.3%) were infrastesticular, and 43 (53.1%) were parastesticular. The diameter of the lymphatic vessels ranged from 1.2 to 12.6 mm (mean = 3.8 mm) at the site of the adult worm nests. Mean vessel diameter at the site of nests in the suprastesticular area was 4.5 mm, compared with 3.5 mm and 3.3 mm in the parastesticular and infrastesticular areas, respectively ($P = 0.03$). Lymphatic vessel diameter was not associated with the number of adult worm nests or with microfilarial density.

Sixty-four (79%) of 81 nests were detected using the 3.5-MHz probe (Figure 2). All of these nests were detected within 30–60 sec on each of the three examinations. Detection of the filaria dance sign was influenced by the diameter of the lymphatic vessel (as measured with the 7.5-MHz probe) and the location of the adult worm nest. At the site of nests that were detected with the 3.5-MHz probe, the mean diameter of the lymphatic vessels was 4.3 mm (range = 2.2–12.6), compared with 1.7 mm (range = 1.2–2.7) for nests that were not detected with this probe ($P = 0.0001$). Vessel diameter strongly influenced the sensitivity of ultrasound; the 3.5-MHz transducer detected all 54 nests > 2.7 mm in diameter, 10 (76.9%) of 13 nests with vessel diameters 2.2–2.7 mm, and none of 14 nests < 2.2 mm in diameter ($P < 0.00001$). Sensitivity was also influenced by location of the adult worm nest. Using the 3.5-MHz transducer, we were

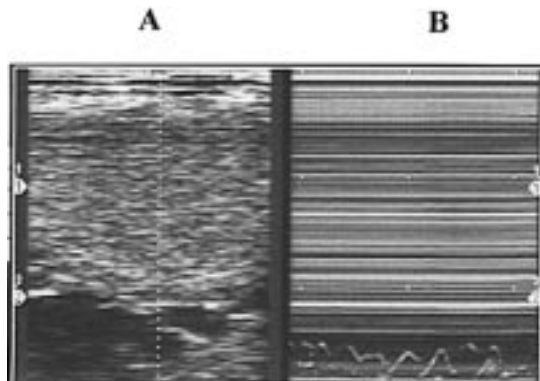


FIGURE 1. Ultrasound image of left hemiscrotal area in an asymptomatic 22-year-old man, obtained with a 7.5-MHz transducer. A B-mode image (A) shows the left testis and lymphangiectasia. An M-mode image (B) shows the wave pattern characteristic of the filaria dance sign.

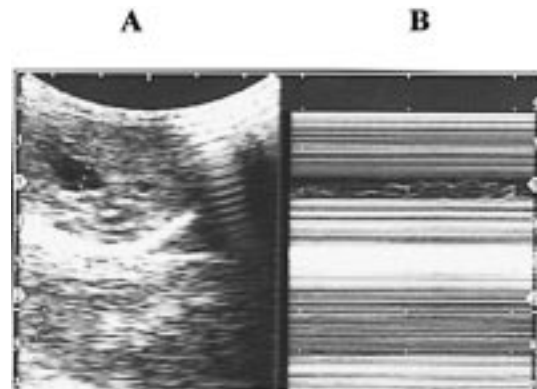


FIGURE 2. Ultrasound image of the same patient shown in Figure 1 obtained using a 3.5-MHz transducer. A B-mode image (A) shows lymphangiectasia at the site of the adult worms. The filaria dance sign in the M-mode image (B) is similar to that seen with the 7.5-MHz transducer (Figure 1).

able to detect all 24 suprastesticular nests, 12 (85.7%) of 14 infrastesticular nests, and 28 (65.1%) of 43 parastesticular nests ($P = 0.003$). Within lymphatic vessels of similar diameter, however, this relationship between nest location and sensitivity of the 3.5-MHz probe was no longer statistically significant. Sensitivity of the 3.5-MHz transducer was not influenced by patient age or microfilarial density, or by whether the nest was located in the left or right hemiscrotum. None of the 20 men who initially tested negative for the filaria dance sign using the 7.5-MHz transducer tested positive with the 3.5-MHz probe on any of the three examinations (100% specificity).

Of 41 men with a detectable filaria dance sign using the 7.5-MHz transducer, 35 (85.4%) were found to have one or more adult worm nests on examination with the 3.5-MHz probe. In 25 of these men, the 3.5-MHz probe detected all the nests that had been observed using the 7.5-MHz probe; in the remaining 10 men, some, but not all nests (50–67%) were detected. The sensitivity of the 3.5-MHz transducer was not influenced by the number of nests detected with the 7.5-MHz transducer.

DISCUSSION

Ultrasound examination of the scrotal area using a 7.5-MHz transducer has been shown to be useful for diagnosis of *W. bancrofti* infection and for assessing the efficacy of antifilarial drugs against the adult worm.^{9, 10, 15, 17, 18} The sensitivity of the 7.5-MHz transducer is quite high. Although one study suggested that the filaria dance sign could be detected in as few as 80% of men with *W. bancrofti* microfilariaemia,¹³ subsequent studies have demonstrated that ultrasound may be more sensitive than detection of either microfilaria or circulating filarial antigen in peripheral blood, particularly when microfilarial density is low (Dreyer G, unpublished data). For example, in a study by Rocha and others, 10 (14%) of 73 men who were microfilaria-negative in 16 ml of filtered blood had *W. bancrofti* detected on ultrasound; only six of these men had detectable levels of circulating filarial antigen (Og4C3).¹¹

The current study indicates that a 3.5-MHz probe can also be used to detect the filaria dance sign of *W. bancrofti* with a relatively high sensitivity (79% of adult worm nests and 85% of infected men) and specificity (100%). The sensitivity of the 3.5-MHz and 7.5-MHz transducers was equivalent when the diameter of the lymphatic vessel was greater than 2.7 mm. Detection of the filaria dance sign with the 3.5-MHz transducer was unreliable when the lymphatic vessel diameter was less than 2.7 mm. Thus, for practical purposes, the limit of detection for the 3.5-MHz probe was reached at a vessel diameter of 2.7 mm. For the 7.5-MHz probe, the limit of detection appears to be at a vessel diameter of approximately 1 mm.¹² Thus, when maximum resolution of the ultrasound image is required, such as in studies of drug efficacy, the 7.5-MHz transducer should continue to be used.

The sensitivity of ultrasound with a 3.5-MHz transducer compares favorably with that of examination of capillary blood for microfilaria, particularly in persons with low microfilarial densities. Examination of 20–60 μ l of capillary blood (standard volumes for epidemiologic surveys) detects as few as 26–52% of infected persons who have microfilarial

densities of 1–30/ml in venous blood.²⁰ In contrast, among eight men in this study who had microfilarial densities ≤ 30 /ml venous blood, ultrasound examination with the 3.5-MHz probe correctly identified six (75%) as infected.

These findings have important implications for the use of ultrasound as a tool for rapid epidemiologic assessment of lymphatic filariasis. In light of recent findings that single-dose ivermectin or diethylcarbamazine can profoundly suppress *W. bancrofti* microfilariaemia for periods of 6–24 months,¹ the International Task Force for Disease Eradication has classified lymphatic filariasis as a potentially eradicable disease.²¹ As in the eradication programs for smallpox and dracunculiasis,²² epidemiologic techniques must be developed to rapidly identify communities with active transmission of *W. bancrofti* so that appropriate interventions can be focused on these communities.^{23, 24}

Ultrasound has several features that make it attractive as a rapid assessment tool, including acceptability, convenience, and sensitivity. Patient acceptance of ultrasound in studies of lymphatic filariasis has been high, not only in Brazil, but in India and Haiti, where transducers of 5.0 MHz or greater have been used to visualize adult *W. bancrofti* (Kumaraswami V, unpublished data and Streit T, unpublished data). Ultrasound units equipped with 3.5-MHz transducers are increasingly available for obstetrics, and portable machines are now made for field use.⁷

The microfilaria of *W. bancrofti* are generally nocturnally periodic; i.e., they appear in highest concentrations in the peripheral blood late at night, during the period of most intense biting of the mosquito vector.²⁰ Therefore, detection of microfilariae in the blood, which is the current standard for diagnosis, must be done at night. This nocturnal periodicity has created considerable difficulties for epidemiologic studies of bancroftian filariasis. Because the ultrasound image of adult *W. bancrofti* (the filaria dance sign) is remarkably stable with time, one advantage of ultrasound examination, which is shared with the recently developed antigen detection assays,^{25, 26} is that it can be done at any time of the day or night.

For rapid epidemiologic assessment, it may be possible to add ultrasound to physical examinations required for certain types of employment, such as the military. Indeed, in some areas where filariasis is endemic, hydrocele is a basis for exclusion from military service. In these settings, ultrasonographic screening and data on residential location could be used to identify areas with transmission of *W. bancrofti*. Ultrasound may also prove useful as one of several tools to certify that lymphatic filariasis has been eliminated from specified areas. In addition to detection of the adult worm, ultrasound examination of the scrotal area can detect subclinical morbidity associated with filarial infection, including lymphangiectasis and hydrocele (Figure 3).¹² Because lymphatic vessel diameter tended to be greater at the site of adult worms in suprastesticular locations in the present study, investigators involved in rapid assessment with a 3.5-MHz transducer may wish to focus on these locations if examination time is limited.

Potential disadvantages of ultrasound for rapid epidemiologic assessment include a lack of ultrasound machines in some areas, a current shortage in developing countries of persons with training in ultrasonography or in detection of

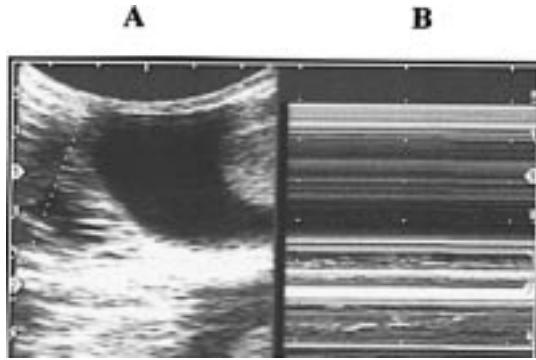


FIGURE 3. Ultrasound image (3.5-MHz transducer) of the scrotal area in an 18-year-old man. In the B-mode image (A), lymphangiectasia is visible on the left side of the screen and a hydrocele is seen adjacent to the left testis. In the M-mode image (B), wave patterns characteristic of the filaria dance sign are seen in two separate nests of adult *Wuchereria bancrofti* at the bottom of the image. At the top of the image where hydrocele is present, no waves can be seen in the M-mode.

the filaria dance sign, and a sensitivity that, although comparable to other methods, is less than 100%. In addition, the precise relationship between ultrasonographic detection of adult *W. bancrofti* in men and the level of filarial transmission in the community from which they come is currently unknown. At present, ultrasound is useful as a diagnostic tool primarily in adult men. Based on clinical,²⁷⁻³⁰ pathologic,²⁹⁻³¹ and ultrasound¹³ evidence, the scrotal area appears to be a preferred site of adult *W. bancrofti* in men. Although the filaria dance sign has been detected in the breast of an infected woman,¹⁶ the preferred locations of adult *W. bancrofti* in women and children remain a mystery. These facts should not diminish the potential usefulness of ultrasound as a tool for rapid epidemiologic assessment, the goal of which is to identify affected communities. Indeed, physical examinations of men for hydrocele have already been recommended as rapid assessment techniques. This indicator appears to correlate well with the prevalence of *W. bancrofti* microfilaremia in the community, even though only half the population is eligible for such screening.²³

In an earlier study, we found that microfilarial density was higher in men with bilateral filarial dance signs than in men with unilateral involvement.¹³ The results of the current study confirm these earlier findings and demonstrate further that microfilarial density is significantly associated with the number of adult worm nests detected by ultrasound.

In summary, ultrasonographic examination with a 3.5-MHz transducer appears to be both sensitive and specific for adult *W. bancrofti* in the scrotal area of infected men. The use of ultrasound for rapid epidemiologic assessment merits further consideration.

Acknowledgments: We thank the men who participated in the study.

Financial support: The study was supported by the UNDP/World Bank/WHO Special Program for Research and Training in Tropical Diseases, FIOCRUZ (Programa de Apoio a Pesquisa Estrategica em Saude II), Fundacao de Amparo a Ciencia e Tecnologia Governo do Estado de Pernambuco (0157.2.13/94 and BFT 0622-2.13/95), and Fundacao Nacional de Saude.

Authors' addresses: Gerusa Dreyer and Abiel Santos, Departamento

de Parasitologia, Centro de Pesquisas Aggeu Magalhaes-FIOCRUZ, Av. Moraes Rego S/N Cidade Universitaria, CEP 50670-420, Recife PE, Brazil. Joaquim Noroes, Hospital das Clinicas, Universidade Federal de Pernambuco, Recife, Brazil. Fernando Amaral, Mediac, Memorial Imagem e Diagnostico, Recife, Brazil. David Addiss, Division of Parasitic Diseases, Mailstop F-22, National Center for Infectious Diseases, Centers for Disease Control and Prevention, 4770 Buford Highway, Chamblee, GA 30341-3724.

Reprint requests: Gerusa Dreyer, Departamento de Parasitologia, Centro de Pesquisas Aggeu Magalhaes-FIOCRUZ, Av. Moraes Rego s/n Cidade Universitaria, CEP 50670-420, Recife, PE, Brazil.

REFERENCES

1. WHO/CTD/TDR, 1994. *Strategies for Control of Lymphatic Filariasis Infection and Disease*. Report of a WHO/CTD/TDR Consultative Meeting Held at the Universiti Sains, Malaysia, Penang, Malaysia, August 22-24, 1994. (TDR/CTD/FIL/PE-NANG/94.1). Geneva: World Health Organization.
2. Gyapong JO, Gyapong M, Evans DB, Aikins MK, Adjei S, 1996. The economic burden of lymphatic filariasis in northern Ghana. *Ann Trop Med Parasitol* 90: 39-48.
3. Gyapong M, Gyapong JO, Adjei S, Vlassof C, Weiss M, 1996. Filariasis in northern Ghana: some cultural beliefs and practices and their implications for disease control. *Soc Sci Med* 43: 235-242.
4. Dreyer G, Norões J, Addiss D, 1997. The silent burden of sexual disability associated with lymphatic filariasis. *Acta Trop* 63: 57-60.
5. World Health Organization, 1995. *The World Health Report 1995: Bridging the Gaps*. Geneva: World Health Organization.
6. Hatz C, Jenkins JM, Tanner M, eds., 1992. Ultrasound in schistosomiasis. *Acta Trop* 51: 1-100.
7. Houston S, 1991. Ultrasound: appropriate technology for tropical field work. *Trans R Soc Trop Med Hyg* 85: 321-323.
8. Amaral F, Dreyer G, Figueredo-Silva J, Noroes J, Cavalcanti A, Curtis Samico S, Santos A, Coutinho A, 1994. Adult worms detected by ultrasonography in human bancroftian filariasis. *Am J Trop Med Hyg* 50: 753-757.
9. Dreyer G, Addiss D, Norões J, Amaral F, Rocha A, Coutinho A, 1996. Direct assessment of the adulticidal efficacy of repeat high-dose ivermectin in bancroftian filariasis. *Trop Med Int Health* 1: 427-432.
10. Norões J, Dreyer G, Santos A, Mendes VG, Medeiros Z, Addiss D, 1997. Assessment of the efficacy of diethylcarbamazine on adult *Wuchereria bancrofti* in vivo. *Trans R Soc Trop Med Hyg* 91: 78-81.
11. Rocha A, Addiss D, Ribiero ME, Norões J, Baliza M, Medeiros Z, Dreyer G, 1996. Evaluation of the Og4C3 ELISA in *Wuchereria bancrofti* infection: infected persons with undetectable or ultra-low microfilarial densities. *Trop Med Int Health* 1: 859-864.
12. Norões J, Addiss D, Santos A, Medeiros Z, Coutinho A, Dreyer G, 1996. Ultrasonographic evidence of abnormal lymphatic vessels in young men with adult *Wuchereria bancrofti* infection in the scrotal area. *J Urol* 156: 409-412.
13. Norões J, Addiss D, Amaral F, Coutinho A, Medeiros Z, Dreyer G, 1996. Occurrence of adult *Wuchereria bancrofti* in the scrotal area of men with microfilaremia. *Trans R Soc Trop Med Hyg* 90: 55-56.
14. Dreyer G, Amaral F, Norões J, Medeiros Z, 1994. Ultrasonographic evidence for stability of adult worm location in bancroftian filariasis. *Trans R Soc Trop Med Hyg* 88: 558.
15. Amaral F, Noroes J, Dreyer G, 1995. Uso da ultra-sonografia no diagnostico da filariose linfatica escrotal - relato de dois casos. *Radiol Bras* 28: 217-219.
16. Dreyer G, Brandao AC, Amaral F, Medeiros Z, Addiss D, 1996. Detection by ultrasound of living adult *Wuchereria bancrofti* in the female breast. *Mem Inst Oswaldo Cruz* 91: 95-96.
17. Dreyer G, Amaral F, Norões J, Medeiros Z, Addiss D, 1995. A new tool to assess *in vivo* the adulticidal efficacy of antifilarial

- drugs for bancroftian filariasis. *Trans R Soc Trop Med Hyg* 89: 225–226.
18. Dreyer G, Norões J, Amaral F, Nen A, Medeiros Z, Coutinho A, Addiss D, 1995. Direct assessment of the adulticidal efficacy of single-dose ivermectin for bancroftian filariasis. *Trans R Soc Trop Med Hyg* 89: 441–443.
 19. Dreyer G, Santos A, Norões J, Rocha A, Addiss D, 1996. Amicrofilaremic carriers of adult *Wuchereria bancrofti*. *Trans R Soc Trop Med Hyg* 90: 288–289.
 20. Dreyer G, Pimentel A, Medeiros Z, Beliz F, Moura I, Coutinho A, Dias de Andrade L, Rocha A, Mauricio da Silva L, Piessens W, 1996. Studies on periodicity and intravascular distribution of *Wuchereria bancrofti* microfilaria in paired samples of capillary and venous blood from Recife, Brazil. *Trop Med Int Health* 1: 264–272.
 21. Centers for Disease Control and Prevention, 1993. Recommendations of the International Task Force for Disease Eradication. *MMWR Morb Mortal Wkly Rep* 42: 1–38.
 22. Richards F, Hopkins D, 1989. Surveillance: the foundation for control and elimination of dracunculiasis in Africa. *Int J Epidemiol* 18: 934–943.
 23. Gyapong JO, Adjei S, Gyapong M, Asamoah G, 1996. Rapid community diagnosis of lymphatic filariasis. *Acta Trop* 61: 65–74.
 24. Ramzy, RMR, Hafez ON, Gad AM, Faris R, Harb M, Buck AA, Weil GJ, 1994. Efficient assessment of filariasis endemicity by screening for filarial antigenaemia in a sentinel population. *Trans R Soc Trop Med Hyg* 88: 41–44.
 25. Lammie PJ, Hightower AW, Eberhard ML, 1994. The age-specific prevalence of antigenemia in a *Wuchereria bancrofti*-exposed population. *Am J Trop Med Hyg* 51: 348–355.
 26. Weil GJ, Lammie PJ, Weiss N, 1997. The ICT filariasis test: a rapid format antigen test for diagnosis of bancroftian filariasis. *Parasitol Today* 13: 401–404.
 27. Dreyer G, Coutinho A, Miranda D, Noroes J, Rizzo JA, Galdino E, Rocha A, Medeiros Z, Andrade LD, Santos A, Figueredo-Silva J, Ottesen EA, 1995. Treatment of bancroftian filariasis in Recife, Brazil: a two-year comparative study of the efficacy of single treatment with ivermectin or diethylcarbamazine. *Trans R Soc Trop Med Hyg* 89: 98–102.
 28. Dreyer G, Pires ML, Andrade LD, Lopes E, Medeiros Z, Tenorio J, Coutinho A, Noroes J, Figueredo-Silva J, 1994. Tolerance of diethylcarbamazine by microfilaraemic and amicrofilaremic individuals in an endemic area of Bancroftian filariasis. *Trans R Soc Trop Med Hyg* 92: 32–34.
 29. Figueredo-Silva J, Jungmann P, Noroes J, Piessens WF, Coutinho A, Brito C, Rocha A, Dreyer G, 1996. Histological evidence for adulticidal effect of low doses of diethylcarbamazine in bancroftian filariasis. *Trans R Soc Trop Med Hyg* 90: 192–194.
 30. Wartman WB, 1947. Filariasis in American armed forces in World War II. *Medicine* 26: 333–394.
 31. Galindo L, von Lichtenberg F, Baldizon C, 1962. Bancroftian filariasis in Puerto Rico: infection pattern and tissue lesions. *Am J Trop Med Hyg* 11: 739–748.